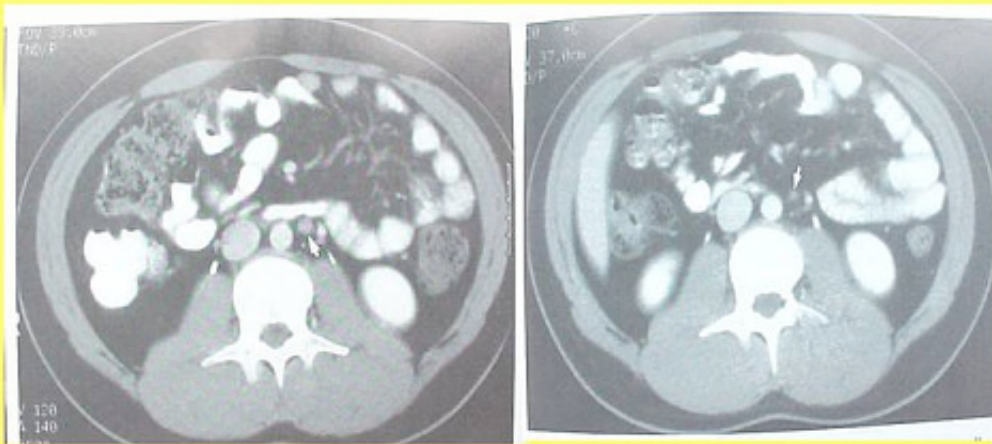


Metastatic Colon Cancer

Case History:

The 59 year old Mrs. A.H. was diagnosed with a metastatic colon cancer. Several enlarged lymph nodes, close to the abdominal aorta, were found with CT-scan suspicious for metastases in February 2002. There was also evidence of liver involvement. Treatment with loco-regional hyperthermia and AVEMAR[®] for several months produced significant reduction of the metastatic lesions.

Reduction of lymphnode metastases under AVEMAR[®] therapy



A.H., 59 years, Feb 2002

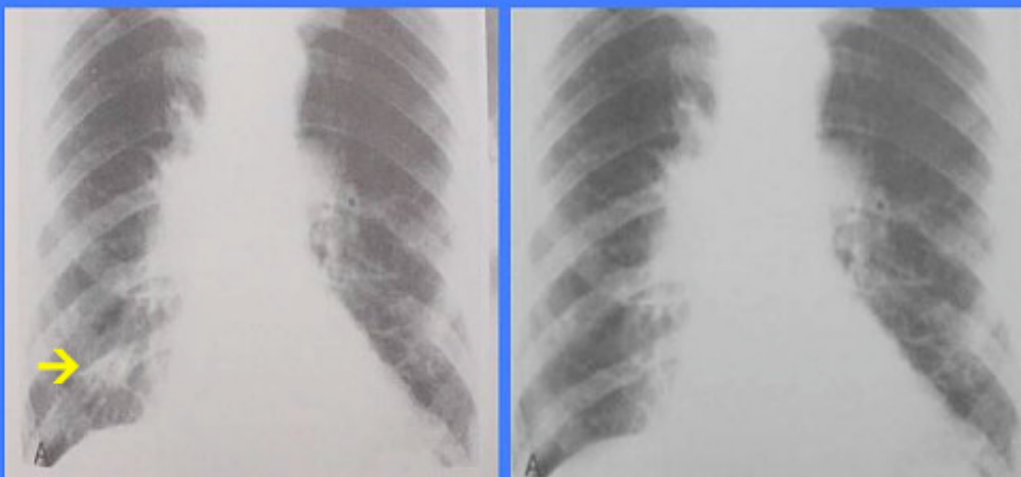A.H., 59 years, Oct 2002

Metastatic Prostate Cancer

Case History:

The 63 year old Mr. K.B. was diagnosed with a metastatic prostate carcinoma. A large lung metastasis caused recurrent cough , and his bone metastases caused considerable pain not well responding to therapy even with strong pain killers. Treatment with ProstaSol (a phytotherapeutic compound with efficacy in prostate cancer) and AVEMAR[®] for about 9 months caused complete resolution of the lung lesion and a marked reduction in bone metastases and cancer related pain.

Reduction of lung metastasis under therapy with ProstaSol and AVEMAR[®]



K.R., 63 years, 20.4.2002

K.R., 63 years, 14.1.2003